

# Posterior Cruciate Ligament Reconstruction With Hamstring Tendons Using a Suspensory Device for Tibial Fixation and Interference Screw for Femoral Fixation

Alejandro Espejo-Baena, M.D., Alejandro Espejo-Reina, M.D., M.Sc.,  
María Josefa Espejo-Reina, M.D., and Maximiano Lombardo-Torre, M.D.

**Abstract:** A technique for posterior cruciate ligament reconstruction is presented. Autologous hamstring tendons are selected as a graft. An interference screw is used for femoral fixation. A suspension device is used for tibial fixation to bring the fixation closer to the articular end of the tibial tunnel. Single diameter tunnels of the same diameter as the graft are created in an outside-in direction.

Posterior cruciate ligament (PCL) reconstruction has received increasing attention in recent years.<sup>1</sup> Different techniques have been described looking for the ideal PCL reconstruction. The number of bundles (single or double) and the fixation technique (transtibial or inlay) have been discussed.<sup>2</sup> Hamstring tendons are frequently selected as a graft when a transtibial technique is performed. Interference screws are one of the most popular fixation devices in ligament graft fixation.

Sometimes, autografts for PCL reconstruction are not long enough in the transtibial technique because the tibial tunnel is longer than said grafts. There have been several attempts to bring the tibial fixation closer to the articular end of the tibial tunnel to solve this problem.<sup>3</sup> The purpose of this work is to describe a technique for PCL reconstruction (Video 1, Table 1, Fig 1) with the following features:

- Use of autologous hamstring tendon graft (tibialis tendon allograft could be used instead)

- Single diameter drilling of tibial and femoral tunnels
- Transtibial passage of the graft
- Tibial fixation with a suspension device (G-Lok; Stryker, Kalamazoo, CA)
- Femoral fixation with an interference screw (Bio-steeon; Stryker)

## Technique

### Patient Positioning, Portals, and Arthroscopic Exploration

The patient is given a regional or general anesthetic and is positioned supine. An ischemia cuff is used, and the limb is supported by a leg holder with the knee at 90° of flexion.

We generally use a central transtendinous portal for cruciate ligament reconstruction. An anteromedial portal is created, and all intra-articular structures are checked with the aid of a probe (if necessary, an additional anterolateral portal is used). The PCL damage is identified, and any associated injuries are treated. An accessory posteromedial portal is then created to properly visualize the articular end of the tibial tunnel and to facilitate graft passage.<sup>4</sup>

### Graft Harvesting and Preparation

Once all intra-articular injuries have been addressed, a 3-cm oblique skin incision is made medially to the anterior tibial tuberosity (Fig 2) to harvest the semitendinosus and gracilis tendons and to create the tibial tunnel. The tendons are harvested with a standard

From Hospital Universitario Virgen de la Victoria (A.E.-B., A.E.-R., M.L.-T.), Málaga; Hospital Vithas Parque San Antonio (A.E.-B., A.E.-R.), Málaga; and Hospital Comarcal de Antequera (M.J.E.-R.), Antequera, Spain.

The authors report that they have no conflicts of interest in the authorship and publication of this article.

Received June 29, 2016; accepted September 10, 2016.

Address correspondence to Alejandro Espejo-Reina, M.D., M.Sc., Clínica Espejo, Paseo Reding 9, 1°-C, 29016 Málaga, Spain. E-mail: [alesre001@gmail.com](mailto:alesre001@gmail.com)

© 2016 by the Arthroscopy Association of North America. Open access under CC BY-NC-ND license.

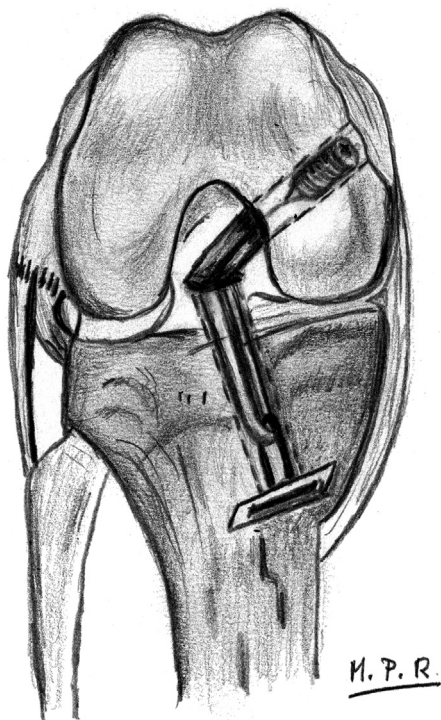
2212-6287/16621

<http://dx.doi.org/10.1016/j.eats.2016.09.019>

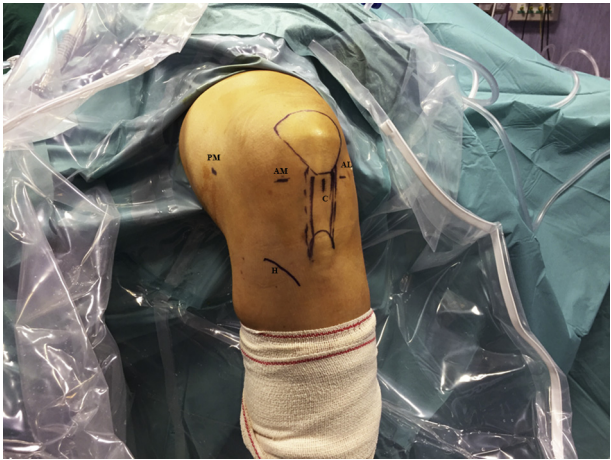**Table 1.** Step-by-Step Details of Technique

1. Patient positioning
  - a. Supine with limb in a leg holder at 90° of flexion
  - b. General or regional anesthetic
  - c. Transtendinous, anteromedial, and posteromedial portals
2. Graft harvesting and preparation
  - a. Semitendinosus and gracilis autologous tendons
  - b. A G-Lok device with a 20 mm loop is used, and it is attached to its expansion piece (G-Lok XL) to increase the contact area with the tibia
  - c. Both ends knotted together forming a closed loop
3. Intra-articular preparation
  - a. Remnant cleaning
  - b. PCL fossa cleaning through posteromedial portal
4. Tunnels
  - a. Outside-in direction
  - b. Same diameter as graft
  - c. Two different arms for Stryker Universal ACL Instrumentation System
    - i. Straight arm for femoral fixation (guide open to 80°)
    - ii. Concave arm for tibial fixation (guide open to 45°)
5. Graft passage and fixation
  - a. Graft passage in caudo-cranial direction from anterior cortex of tibia
  - b. Posteromedial portal used to pull graft inside joint
  - c. Transtendinous portal used to bring graft to anterior aspect of knee
  - d. Suspension device attached to anterior cortex of tibia; gentle traction of threads and anterior drawer strength applied

PCL, posterior cruciate ligament.

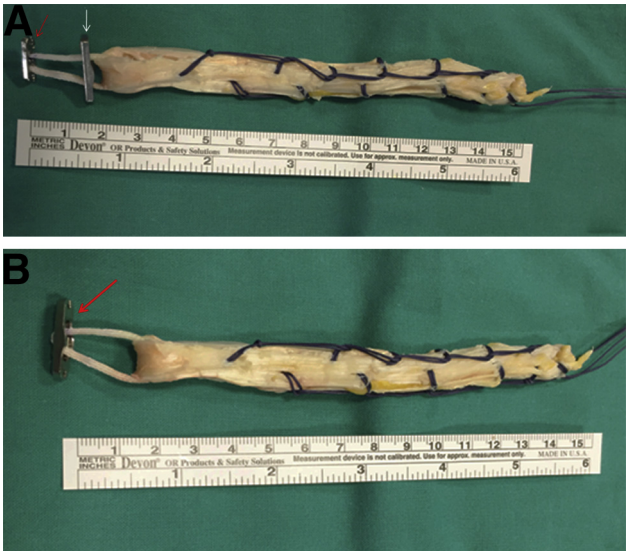

**Fig 1.** Diagram of technique performed on a right knee. A suspensory device with its expansion piece can be seen on the anterior cortex of the tibia. The loop length can be adapted according to the tunnel's and graft's lengths: Even short grafts can be used for this reason. Femoral fixation is achieved using an interference screw.



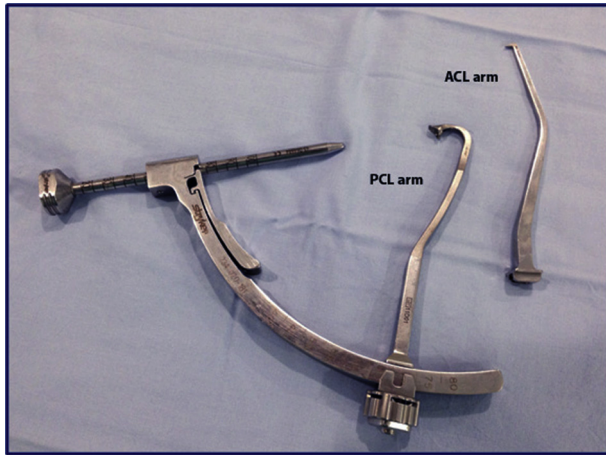
**Fig 2.** Patient positioning. A left knee is shown. The limb is placed in a leg holder at 90° of flexion. The central transtendinous portal (C) is used for visualization. The anteromedial portal (AM) is used as the working portal. The anterolateral portal (AL) can be used, if necessary, as an auxiliary portal, for procedures such as meniscal suturing. The posteromedial portal (PM) is used for determination of the proper location of the tibial insertion of the posterior cruciate ligament, cleaning of the remnants, tunnel creation, and graft passage. The incision for the hamstring tendons (H) is medial to the anterior tibial tuberosity.

tendon stripper (Stryker Universal ACL Instrumentation System). Both tendons are prepared on an auxiliary table by the assistant surgeon and joined by means of a bioabsorbable suture, which will serve as a traction thread. The ends of the graft are knotted together to



**Fig 3.** Hamstring tendon graft prepared for insertion, with the suspensory device and its additional length device. Both ends of the graft are knotted together to improve biomechanical resistance of the tibial fixation. (A) Both the suspensory device (red arrow) and its expansion piece (white arrow) are shown separated for a better understanding of the construct. (B) Both devices are attached (arrow) as in the final position.



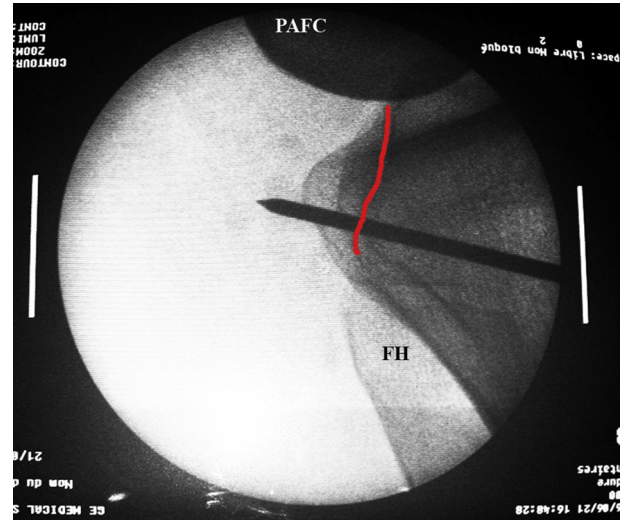


**Fig 4.** The guide of the Stryker Universal ACL Instrumentation System is used for tunnel creation. The posterior cruciate ligament (PCL) arm is used open to 45° to drill the tibial tunnel, and the anterior cruciate ligament (ACL) arm is used open to 80° to drill the femoral tunnel.

form a closed loop.<sup>5</sup> A suspension device (G-Lok) is placed in position beforehand with a loop as long as necessary, depending on the graft's and tibial tunnel's lengths. This is accompanied by a further device of greater length (G-Lok XL; Stryker) to facilitate cortical fixation once the whole of the tunnel has been created with a diameter identical to that of the graft (Fig 3).

### Intra-articular Preparation

Meanwhile, PCL remnants are cleared up by the main surgeon, and the lateral wall of the medial femoral condyle is prepared using a radiofrequency probe and a resector (Video 1). The posterior aspect of the proximal tibia is approached through the accessory posteromedial portal, with the arthroscope set through the

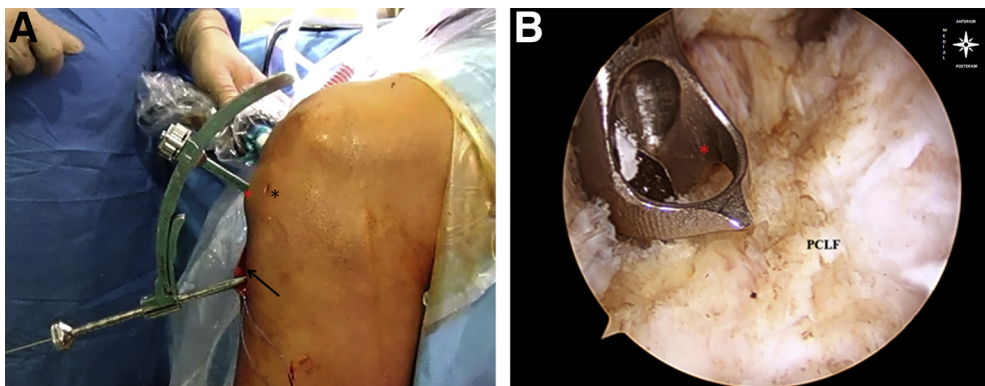


**Fig 6.** Lateral radiograph showing the posterior aspect of the left knee. A guide pin is inserted through the tibia, and its tip is located at the distal end of the posterior cruciate ligament fossa (red line). (FH, fibular head; PAFC, posterior aspect of femoral condyles.)

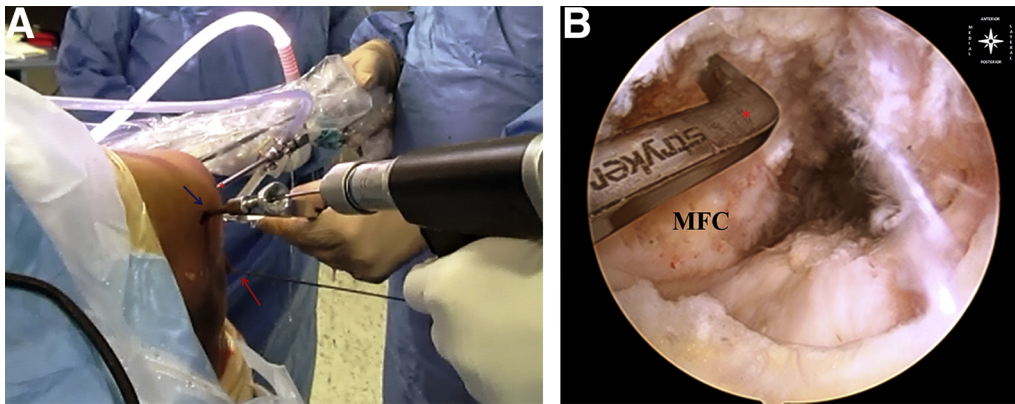
central transtendinous portal, to locate the tibial insertion of the PCL (PCL fossa)<sup>4</sup> and to clear up the remnants of the tibial insertion of the PCL.

### Tunnels

Both tunnels are created in an outside-in direction, using a guide with 2 different arms (Stryker) (Video 1, Fig 4). The femoral tunnel is created using the straight arm designed for anterior cruciate ligament (ACL) tibial tunnel reconstruction, and the tibial tunnel is created with an arm with a higher concave curvature to avoid the tibial spines (Fig 4). The intra-articular end of the tibial tunnel is approached through the transtendinous



**Fig 5.** Left knee. (A) Extra-articular view of the posterior cruciate ligament (PCL) arm of the guide open to 45°, inserted through the central transtendinous portal (red asterisk), with the arthroscope introduced through the posteromedial portal. The guide pin is inserted through the guide, which is inserted through the anteromedial tibial approach, used for hamstring harvesting (arrow). The black asterisk indicates the transtendinous portal. (B) Intra-articular view of the PCL guide (asterisk) located on the most distal part of the PCL fossa (PCLF) (arthroscope set through posteromedial portal, guide inserted through anteromedial portal) in the posterior compartment.



**Fig 7.** Left knee. (A) Extra-articular view of the anterior cruciate ligament arm of the guide open to 80°, inserted through the anteromedial portal, with the arthroscope (asterisk) inserted through the central transtendinous portal. The guide pin is inserted through the guide (blue arrow), which is inserted through a medial approach of 2 cm in length on the medial epicondyle. The tibial guide pin can be seen (red arrow) set in place through the anteromedial tibial approach. (B) Detail of the anterior cruciate ligament guide (asterisk) set on the femoral insertion of the posterior cruciate ligament (arthroscope through central portal, guide inserted through anteromedial portal). (MFC, medial femoral condyle.)

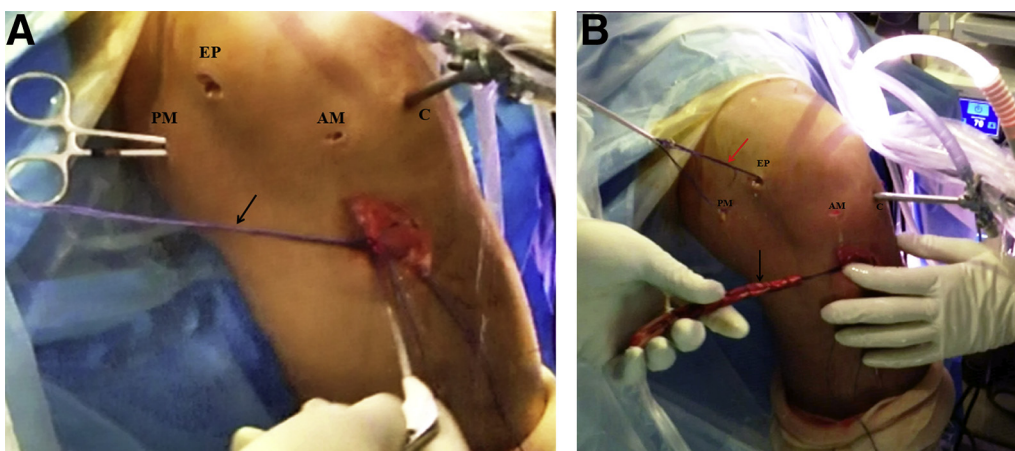
portal with said arm open to 45° (Fig 5); its tip is placed at the distal end of the original PCL fossa. The guide pin is introduced through the incision made for the hamstring tendons from outside-in; its tip should be set on the center of the original footprint of the PCL, approximately 7 mm anterior to the posterior cortex of the PCL facet. Its correct position is checked using anteroposterior and lateral radiographs (Fig 6). The arthroscope is placed through the posteromedial portal to locate the intra-articular tibial end of the tunnel.<sup>4</sup>

The standard ACL arm is used to create the femoral tunnel (Fig 7). It is inserted through the anteromedial portal, open to 80°, with the arthroscope placed through the transtendinous portal. A 1.5-cm incision is made on the medial epicondyle. The guide is then

referenced 8 mm from the edge of the articular surface in the middle of the PCL footprint, leaving a 2-mm bone bridge from the anterior articular surface of the medial femoral condyle. The femoral guide pin is inserted from outside-in. Once the guide pins are set in the correct place, tibial and femoral tunnels are drilled with the same diameter as the graft (Video 1), which has been previously measured using the calibrator of the Stryker Universal ACL Instrumentation System.

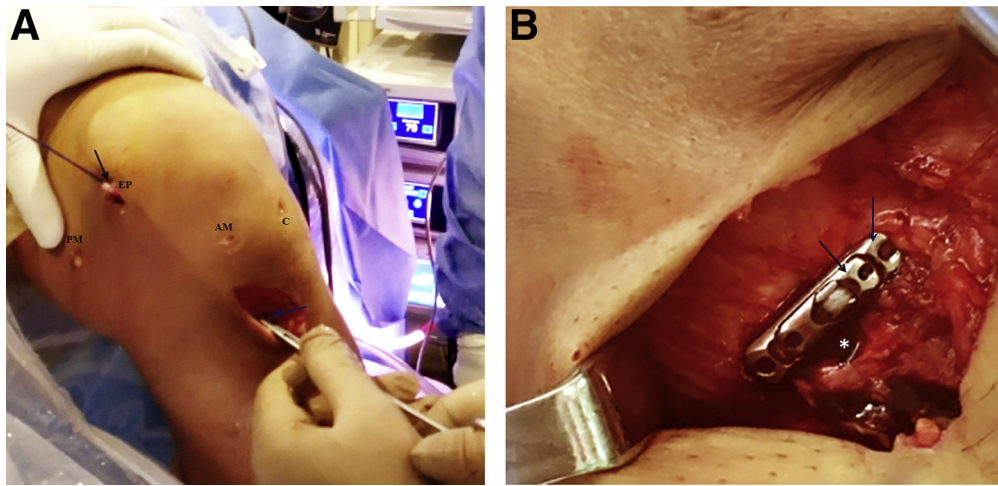
### Graft Passage and Fixation

The graft is passed in a caudo-cranial direction (Video 1). The traction thread is introduced inside the joint through the tibial tunnel (Fig 8) and retrieved with the aid of a grasper through the posteromedial

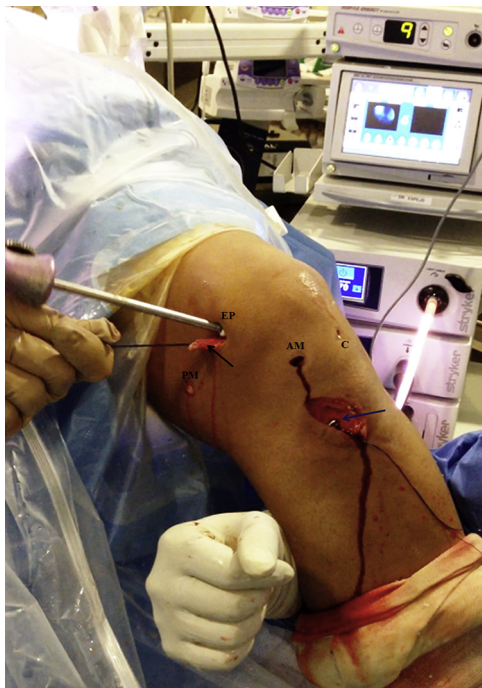


**Fig 8.** Left knee. (A) The traction threads (arrow) are introduced through the extra-articular end of the tibial tunnel. A pincer is introduced through the posteromedial portal (PM) to help the graft pass to the anterior aspect of the joint. The arthroscope is placed through the central transtendinous portal (C). (AM, anteromedial portal; EP, incision over medial epicondyle.) (B) The traction threads (red arrow) are retrieved through the femoral tunnel (medial epicondyle [EP]), and the graft (black arrow) is passed in a caudo-cranial direction by pulling the traction threads, under arthroscopic supervision, with the arthroscope introduced through the central transtendinous portal (C). (AM, anteromedial portal; PM, posteromedial portal.)





**Fig 9.** Extra-articular view of the left knee. (A) Once inserted, the suspension device (blue arrow) is attached to the anterior cortex of the tibia with the aid of a pincer, to avoid slippage into the tunnel, while traction of the traction threads (black arrow) is maintained. (AM, anteromedial portal; C, central transtendinous portal; EP, incision on medial epicondyle; PM, posteromedial portal.) (B) Detail of the fixation device (black arrow) on the anterior cortex of the tibia, at the extra-articular end of the tibial tunnel (asterisk), engaged in the additional length piece (blue arrow).



**Fig 10.** Extra-articular view of the left knee. Fixation of the femoral end of the posterior cruciate ligament graft is performed with the application of anterior drawer strength to the tibia. The suspensory device is attached to the anterior cortex of the tibia (blue arrow) while traction is applied to the traction threads. The screw is introduced through the incision on the medial epicondyle (EP). If the graft is long enough to fit the size of the tunnels, sometimes the remaining part (black arrow) can be seen outside of the joint (it should be further removed). (AM, anteromedial portal; C, central transtendinous portal; PM, posteromedial portal.)

portal. By use of a different grasper, which is inserted through the anteromedial portal, the thread is recovered and brought to the anterior part of the knee, next to the intra-articular end of the femoral tunnel. The first grasper is then introduced from outside through the femoral tunnel and is used to pull the graft and extract it to the medial aspect of the medial epicondyle (Fig 8).

The graft is fixed to the tibia with the composite device to which it has previously been attached. It is fitted to the anterior cortex of the tibia with the aid of a pincer to avoid slippage into the tunnel (Fig 9). The surgeon fixes the graft to the femur from outside-in, applying gentle traction from the threads of the grafts and anterior drawer force with the knee flexed at 90°, using a bioabsorbable interference screw (Biosteon) that is

## Table 2. Advantages and Disadvantages

### Advantages

The main advantage of the described technique is that the loop length can be adapted to the graft's and tunnel's lengths, allowing PCL reconstruction even with short grafts or long tunnels by increasing the length of the loop.

Anatomic position of both tunnels can be easily achieved because they are created independently using the original footprints of the PCL as a landmark.

The posteromedial portal facilitates the passage of the graft in the caudo-cranial direction.

### Disadvantages

The tibial fixation device must be combined with another device of additional length.

Tunnels are created in an outside-in direction, so 2 incisions (1 femoral and 1 tibial) are needed.

PCL, posterior cruciate ligament.

**Table 3.** Tips, Pearls, and Pitfalls**Tips and pearls**

Although it is not essential, we recommend that the central portal should be used to ensure a clear view of the intercondylar notch, including the PCL fossa.

Once the tunnels have been created, the shallow edge should be “planed” to reduce graft friction.

Once the graft is in place, the surgeon should check that the device is properly supported by the tibial cortex.

**Pitfalls**

During its passage through the tunnels, the graft may become snagged. To avoid this, utmost care should be taken when suturing its extremities to ensure that the ends of the stitches are not frayed, distended, or irregular in any way.

The surgeon should check that the graft can be passed with ease through the diameter calibrator. If this is not possible, we recommend enlarging the tunnel diameter by passing the drill bit through the tunnel 1 or 2 more times or by using a drill bit 0.5 mm wider than the graft.

PCL, posterior cruciate ligament.

1 mm larger in diameter than the tunnel and of the maximum length that said tunnel allows (Fig 10).

## Discussion

Many cruciate ligament reconstruction techniques are performed using a suspension device for femoral fixation and an interference screw for tibial fixation, although inverted fixation has also been described.<sup>3,6</sup> Femoral cortical suspension fixation has largely been described for ACL reconstruction<sup>7-9</sup>; however, it has barely been described for PCL reconstruction, and in most of these cases, it has been described for all-inside techniques,<sup>10,11</sup> including non-hardware techniques.<sup>12</sup>

As is known, the tibial tunnel length is longer for transtibial PCL reconstruction than for ACL reconstruction,<sup>3</sup> so a longer graft is needed. The main advantage of this technique using a suspensory device for tibial fixation is that different loop lengths can be used (Table 2); depending on the graft length needed, up to an additional 35 mm can be provided. Furthermore, we enter centrally through the transpatellar portal; this provides us with an optimal view of the intercondylar notch, facilitating the creation of the tunnel and the passage of the graft (Table 3).

As well as in other techniques, an interference screw 1 mm wider than the graft diameter is used for femoral fixation. The main drawback of this technique is that

the fixation device must be combined with another device of additional length.

## References

1. LaPrade CM, Civitaresse DM, Rasmussen MT, LaPrade RF. Emerging updates on the posterior cruciate ligament: A review of the current literature. *Am J Sports Med* 2015;43:3077-3092.
2. Lee YS, Jung YB. Posterior cruciate ligament: Focus on conflicting issues. *Clin Orthop Surg* 2013;5:256-262.
3. Lee YS, Ahn JH, Jung YB, et al. Transtibial double bundle posterior cruciate ligament reconstruction using TransFix tibial fixation. *Knee Surg Sports Traumatol Arthrosc* 2007;15:973-977.
4. Moorman CT III, Murphy Zane MS, Bansai S, et al. Tibial insertion of the posterior cruciate ligament: A sagittal plane analysis using gross, histologic, and radiographic methods. *Arthroscopy* 2008;24:269-275.
5. Prado M, Martín-Castilla B, Espejo-Reina A, Serrano-Fernández JM, Pérez-Blanca A, Ezquerro F. Close-looped graft suturing improves mechanical properties of interference screw fixation in ACL reconstruction. *Knee Surg Sports Traumatol Arthrosc* 2013;21:476-484.
6. Lee YS, Han SH, Kim JH. A biomechanical comparison of tibial back side fixation between suspensory and expansion mechanisms in trans-tibial posterior cruciate ligament reconstruction. *Knee* 2012;19:55-59.
7. Espejo-Baena A, Espejo-Reina A. Anatomic outside-in anterior cruciate ligament reconstruction using a suspension device for femoral fixation. *Arthrosc Tech* 2014;13:e265-e269.
8. Eguchi A, Ochi M, Adachi N, Deie M, Nakamae A, Usman MA. Mechanical properties of suspensory fixation devices for anterior cruciate ligament reconstruction: Comparison of the fixed-length loop device versus the adjustable-length loop device. *Knee* 2014;21:743-748.
9. Kyung HS, Lee HJ, Oh CW, Hong HP. Comparison of results after anterior cruciate ligament reconstruction using a four-strand single semitendinosus or a semitendinosus and gracilis tendon. *Knee Surg Sports Traumatol Arthrosc* 2015;23:3238-3243.
10. Adler GG. All-inside posterior cruciate ligament reconstruction with a GraftLink. *Arthrosc Tech* 2013;2:e111-e115.
11. Prince MR, Stuart MJ, King AH, Sousa PL, Levy BA. All-inside posterior cruciate ligament reconstruction: Graft-Link technique. *Arthrosc Tech* 2015;4:e619-e624.
12. Chen B, Gao S. Double-bundle posterior cruciate ligament reconstruction using a non-hardware suspension fixation technique and 8 strands of autogenous hamstring tendons. *Arthroscopy* 2009;25:777-782.