



# Associated Reconstruction of Anterior Cruciate and Anterolateral Ligaments With Single Asymmetric Hamstring Tendons Graft

Alejandro Espejo-Baena, M.D., Alejandro Espejo-Reina, M.D., M.Sc.,  
Abel Gómez-Cáceres, M.D., Maria Josefa Espejo-Reina, M.D., and  
Jaime Dalla Rosa-Nogales, M.D.

**Abstract:** The anterior cruciate ligament (ACL) rupture is a common disease that accounts for 250,000 cases/year in the United States. The anterolateral ligament (ALL) has been suggested to be an important restraint for rotational instability, and its reconstruction provides a reinforcement to the ACL reconstruction in this aspect, especially in high-demand athletes and in knees with high-grade pivot shift. Different techniques for associated ACL and ALL reconstruction have been described, but the ideal technique remains unclear. Several facts of these techniques may entail a concern to the surgeon, such as the need for several grafts or several bone tunnels. A technique for associated ACL and ALL is presented, using a single hamstring tendons graft, which is prepared asymmetrically, leaving one-third of the length with single diameter and two-thirds with double diameter. A single femoral tunnel is created, using a screw for fixation and differentiation of the grafts. A suspension device is used for tibial fixation, allowing for length adjustment according to the graft's length. The objective of this Technical Note is to provide the orthopaedic surgeon with a resource for ACL and ALL reconstruction even with relatively short grafts, saving bone stock and avoiding the need for allografts.

Complete restoration of the rotational anterolateral stability (ALS) of the knee when performing an anterior cruciate ligament (ACL) reconstruction, which has been considered as a cause of failure,<sup>1</sup> has not been completely achieved, with residual pivot shift remaining in about 25% of the patients,<sup>2</sup> although reconstruction techniques keep improving their biomechanical properties.<sup>3</sup>

Several decades ago, extra-articular anterolateral ligament (ALL) reconstruction techniques were employed

with the aim of restoring said ALS.<sup>4,5</sup> Afterwards, it was thought that a double-bundle reconstruction could improve ALS because it would reproduce ACL anatomy more faithfully.<sup>6</sup> At the beginning of this decade, "anatomic" double-bundle techniques were proposed.<sup>7</sup> Although anatomic double-bundle techniques have shown biomechanical superiority,<sup>8</sup> clinical results are not better than those of the anatomic single-bundle ACL reconstruction<sup>9,10</sup>; this fact and its technical complexity have decreased the use of double-bundle techniques.

In a new trial for restoring rotational stability, and after Claes and colleagues' publication of their anatomic study on ALL,<sup>11</sup> several techniques have been described for the reconstruction of the said ligament, using allografts,<sup>12</sup> artificial grafts,<sup>13</sup> or even hamstring tendons.<sup>14,15</sup>

Femoral cortical suspension is one of the most popular techniques employed for ACL reconstruction using hamstring tendons. With this fixation device, it is very common to have a long redundant piece of the graft, which is usually wasted (Fig 1). The aim of this article is to describe a technique for ACL and ALL reconstruction using a cortical suspension device for tibial ACL fixation and an interference screw for femoral fixation, using

*From the Hospital Vithas Parque San Antonio (A.E-B., A.E-R., J.D.R-N.); Clínica Espejo (A.E-B., A.E-R.); Hospital Universitario Virgen de la Victoria (A.E-B.); Hospital Regional de Málaga (A.G-C.); and Hospital Comarcal de Antequera (M.J.E-R.), Antequera, Málaga, Spain.*

*The authors report that they have no conflicts of interest in the authorship and publication of this article. Full ICMJE author disclosure forms are available for this article online, as supplementary material.*

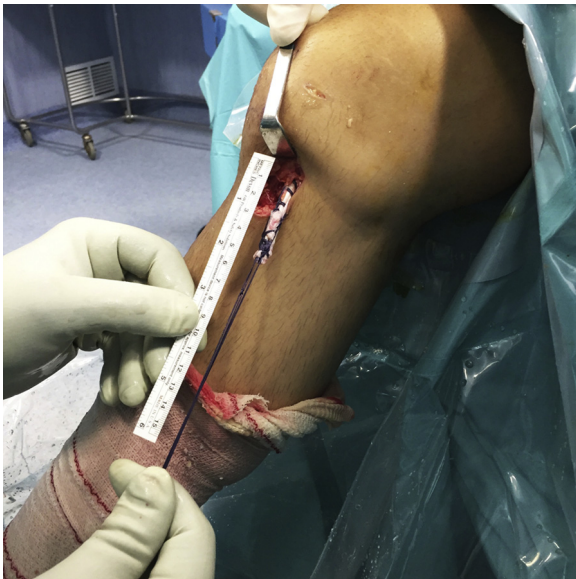*Received March 7, 2017; accepted August 4, 2017.*

*Address correspondence to Alejandro Espejo-Reina, M.D., M.Sc., Clínica Espejo, Paseo Reding 9, 1° C. 29016, Málaga, Spain. E-mail: [espejoreina@clinicadoctorespejo.com](mailto:espejoreina@clinicadoctorespejo.com)*

*© 2017 by the Arthroscopy Association of North America. Published by Elsevier. This is an open access article under the CC BY-NC-ND license (<http://creativecommons.org/licenses/by-nc-nd/4.0/>).*

*2212-6287/17311*

*<http://dx.doi.org/10.1016/j.eats.2017.08.002>*



**Fig 1.** Photograph after a standard isolated ACL reconstruction with autologous hamstring tendons on a right knee where a G-Lok XL of 15 mm has been used for femoral fixation and a Biosteon bioabsorbable screw for the tibial one. An almost 6-cm remnant of the graft that would be wasted in other cases can be seen. This remnant is used in this technique for ALL reconstruction by inverting the fixation devices. (ACL, anterior cruciate ligament; ALL, anterolateral ligament.)

the redundant piece of the hamstring tendons graft for percutaneous ALL reconstruction (Fig 2, Video 1, Table 1).

## Technique

### Patient Positioning

The patient is given a regional or general anesthetic and positioned supine. An ischemia cuff is used and the limb is supported by a leg holder with the knee placed at 90° of flexion (Fig 3).

### Arthroscopic Exploration

A central transtendinous portal is generally employed by the authors for cruciate ligament reconstruction. The ACL damage is identified and any associated injuries are treated with the aid of an anteromedial portal (if necessary, an additional anterolateral portal can be used). Meanwhile, ACL remnants are removed and the lateral wall of the medial femoral condyle is prepared using a radiofrequency probe and a resector.

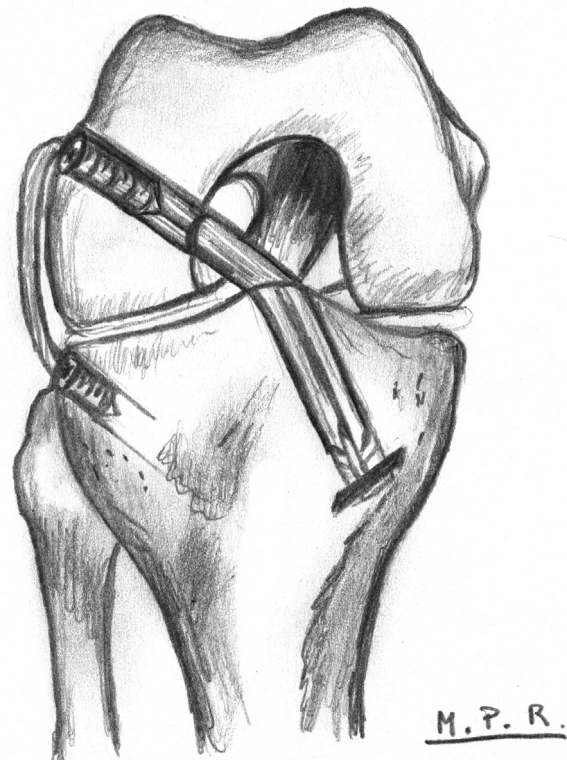
### Graft Harvesting and Preparation

A 3-cm oblique skin incision is made anteromedially to the anterior tibial tuberosity in order to harvest the semitendinosus and gracilis tendons and to create the tibial tunnels. The tendons are harvested with a standard tendon stripper. Both tendons are prepared on an

auxiliary table. The ends of the graft are prepared separately with traction threads: this allows the surgeon to pass the graft asymmetrically (Fig 4) through a suspension device (G-Lok; Stryker, Kalamazoo, MI) attached to its expansion piece (G-Lok XL; Stryker), resulting in 2 arms: a shorter one, for femoral ACL grafting, and a longer one, which will be further used for ALL reconstruction. The length chosen for the loop of the suspension device is variable, according to the tunnel's and the graft's length (10-15 mm are the lengths most commonly used, but longer lengths may be needed if a shorter graft or a longer tunnel is available). An additional device of greater length is attached to the standard one to facilitate cortical fixation once the whole length of the tunnel has been created with a diameter identical to that of the graft.

### Tunnel Creation

Both the femoral and tibial tunnels are created with the aid of an ACL tibial guide (Stryker Endoscopy) (Fig 5). This must be adjustable to at least 80° to ensure the correct positioning of the femoral tunnel. Starting with the femoral tunnel, the arthroscope is inserted through the anteromedial portal and the guide set at the widest



**Fig 2.** Diagram of the technique on a right knee. A suspension device attached to its XL expansion device has been used for tibial fixation, and an interference screw has been employed for the femoral one. The remnant of the graft is used for ALL reconstruction, which is fixed to the tibia with a smaller interference screw. (ALL, anterolateral ligament.)

**Table 1.** Step-by-Step Details of Technique

1. Patient positioning
a. Supine with limb in a leg holder at 90° of flexion
b. General or regional anesthesia
c. Transtendinous and anteromedial portals
2. Graft harvesting and preparation
a. Semitendinous and gracilis autologous tendons
b. A G-Lok device with a 15-mm loop is used (a longer loop can be employed if a short graft or a long tunnel is measured), and it is attached to its expansion piece (G-Lok XL) to increase the contact area with the tibia
c. Both ends are knotted together asymmetrically forming a closed loop, leaving one device's end of the graft with double diameter (the diameter of the ACL graft) and the other end (approximately one-third of the length of the graft) with single diameter (ALL diameter)
3. Intra-articular preparation
a. Remnant cleaning
b. Footprint of ACL identification
4. Tunnels
a. Outside-in direction
b. Same diameter as the doubled graft's
c. 80° opening for femoral tunnel, 55° for tibial tunnel
5. Graft passage and fixation
a. Caudocranial direction from the anterior cortex of the tibia
b. A transtendinous portal is used for vision, and the anteromedial for graft passage
c. Traction threads are recovered through the femoral portal, and the graft is pulled until the suspension device is attached to the tibial cortex
d. Femoral fixation with bioabsorbable screw 1 mm wider than the graft and the tunnel
6. ALL
a. Anatomic location of ALL tibial insertion approached through a 2-cm incision.
b. A guide-pin is inserted in that spot, in the craniocaudal direction, and a tunnel is created with a drill bit of the same diameter as the graft's
c. The single-diameter remnant of the graft is passed percutaneously under the fascia lata to the distal approach performed for ALL tibial insertion
d. The graft is inserted through the tunnel and is fixed with a bioabsorbable screw 1 mm wider than the graft and the tunnel

ACL, anterior cruciate ligament; ALL, anterolateral ligament.

possible angle (the authors usually place the femoral tunnel at 80°) through the central transtendinous portal (Fig 6). If it is possible to identify the bony anatomic landmarks, namely, the bifurcate and intercondylar ridges, the said reference points are used to determine and mark the center of the ACL footprint; if not, the center of the tunnel is established approximately halfway along a line drawn parallel to the posterior margin of the lateral femoral condyle, from deep to shallow, at a distance from the said margin equal to the radius of the femoral tunnel plus 2.5 mm (e.g., 7 mm for a tunnel 9 mm in diameter). A 1.5-cm incision is made in the lateral femoral epicondyle, and a guide needle is introduced with the aid of the ACL reconstruction guide, entering the joint at the pre-determined site. The tibial tunnel is created by

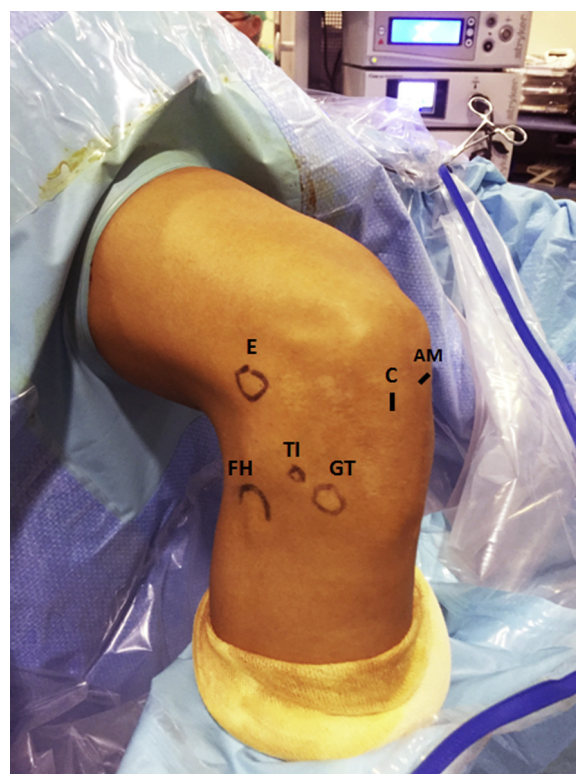
returning the arthroscope to the central portal and introducing the same guide through its anteromedial one, at an angle of 55° (Fig 7). First, a needle is inserted using the guide and positioned at the center of the footprint of the native ACL. Both tunnels are then completed with the aid of a drill bit of identical diameter to that of the graft.

After the graft is passed through the femoral tunnel, a second tibial tunnel is drilled for the ALL graft. A longitudinal 10-mm incision is made over its tibial insertion site (slightly proximal to the midpoint between the Gerdy tubercle and fibular head). A guide pin is inserted through the incision from lateral to medial and from cranial to caudal (Fig 8). Care must be taken to avoid convergence with the first tibial tunnel. A cannulated drill bit of the same diameter as that of the longer end of the graft is used to prepare the tunnel.

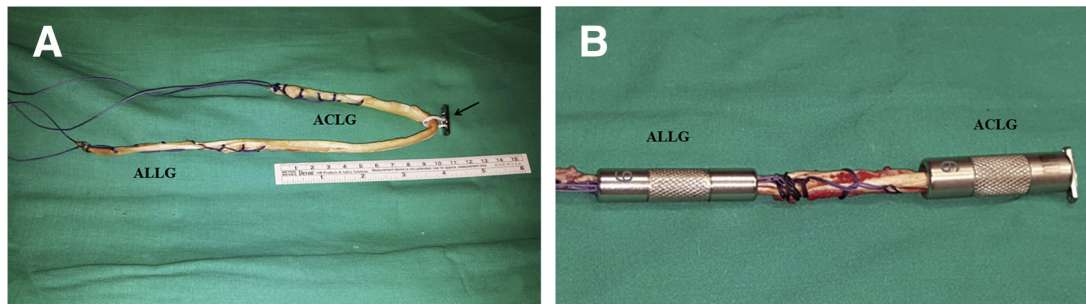
### Graft Pass and Fixation

The graft is introduced from caudal to cranial. The traction threads are inserted into the joint through the ACL tibial tunnel and they are taken out of the joint through the femoral tunnel; the graft is pulled until it passes through both tunnels.

The suspension device with its expansion piece is attached to the anterior cortex of the tibia (Fig 9), and



**Fig 3.** Patient positioning and landmarks; the patient is positioned supine, with the thigh in a leg holder and the knee flexed 90°. (AM, anteromedial portal; C, central portal. E, epicondyle; FH, fibular head; GT, Gerdy's tubercle; TI, tibial insertion of the ALL.)



**Fig 4.** (A) Hamstring tendons graft prepared with both ends knotted. The ACL part of the graft (where a double graft is used) must be at least 9 cm long. The arrow points the tibial fixation device (G-Lok 15 mm attached in its XL device). (B) Calibration of ACL and ALL ends of the graft; 9 mm are measured on the ACL part and 6 mm on the ALL one. (ACL, anterior cruciate ligament; ACLG, anterior cruciate ligament end of the graft; ALL, anterolateral ligament; ALLG, anterolateral ligament end of the graft.)

both ends of the graft are set in an asymmetrical manner. The short arm (9 cm long, approximately) is used together with the middle part of the long arm for the femoral grafting of the ACL. The longer arm (of double length, approximately) will serve as the ALL graft.

Gentle traction of both traction threads is performed until both ends of the graft come out of the femoral cortex; the short arm is screeded to the level of the femoral cortex. Tibial fixation is achieved with the suspension device and its expansion piece (G-Lok and G-Lok XL; Stryker). An interference screw (Biosteon; Stryker) of a diameter 1 mm wider than the graft (Fig 10) is introduced in an outside-in direction while keeping traction from both ends of the graft, achieving ACL reconstruction.

The traction threads are passed percutaneously under the fascia lata, to the tibial anterolateral incision, and they are taken out through this incision (Fig 11). After that, they are threaded in the eyelet of the pin guide (Fig 12), to pass it through the second tibial tunnel from lateral to medial. The graft is pulled with the traction threads, with the knee in neutral rotation and 30° of flexion; it is fixed with a Biosteon screw of a diameter 1 mm wider than the tunnel (Fig 13).

### Postoperative Protocol

- *Weeks 1-2:* Weight-bearing is allowed at home, but elevation of the limb is recommended most of the day. Exercises for muscle activation and active flexion of the knee are recommended as tolerated.
- *Weeks 3-6:* Physiotherapy is performed to gain full range of motion and full quadriceps strength.
- *Weeks 7-12:* Low-impact sports activities (swimming, stationary cycling, etc.) are allowed. Physiotherapy is continued if range of motion or quadriceps strength is not completely achieved.
- *Weeks 13-16:* Five minutes' jogging is allowed daily during the first week. Five-minute increases are implemented weekly, reaching 20-minute jogging sessions at the end of the month.

- *Months 4-6:* No-time limit jogging is allowed. Changes of rhythm and direction begin, increasing their intensity progressively. Specific sport exercises are performed at the end of this period.
- *Months 6-9:* Return to sport.

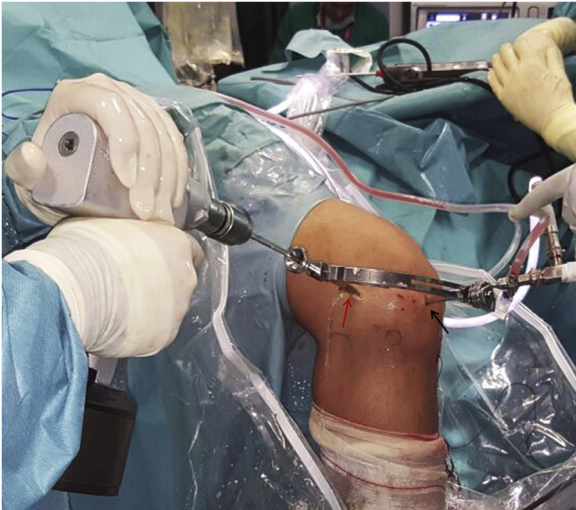### Discussion

The main advantage of this technique is the possibility to perform an anatomic ALL reconstruction associated to the reconstruction of the ACL with a single femoral tunnel and a single graft, using the remaining part of the graft used for ACL reconstruction, and adding only an additional tibial tunnel (Fig 14), by using the suspension fixation device for tibial ACL fixation; this tip facilitates the surgery and adds a minimum extra surgical time to the isolated ACL reconstruction (Tables 2 and 3).

Techniques for lateral extra-articular tenodesis (LET) were often used several decades ago, as isolated procedures<sup>4</sup> or associated to ACL reconstruction.<sup>5</sup> As stated by Slette et al. in their systematic review,<sup>16</sup> in the

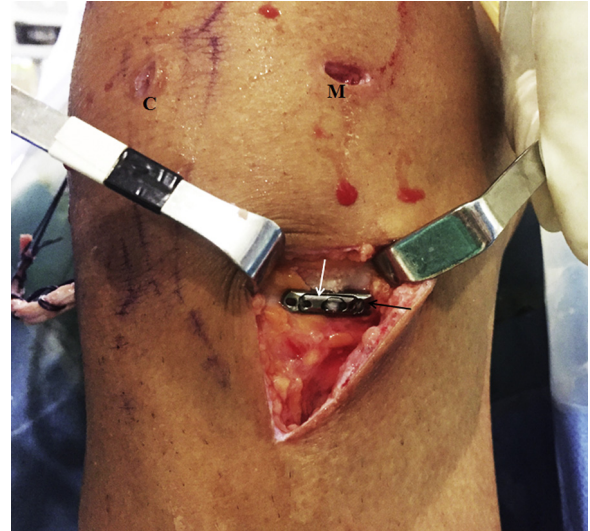


**Fig 5.** The guide used for tunnel drilling, which can provide up to 80° of opening, is shown. It is opened 55° to create the tibial tunnel for ACL reconstruction and 80° to create the femoral one.



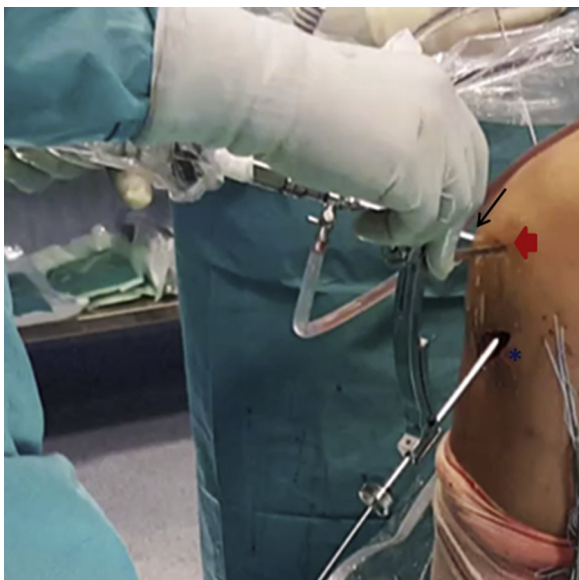
**Fig 6.** Placement of the guide-pin for femoral tunnel drilling through the approach made on the lateral epicondyle (red arrow), with an outside-in technique (right knee), with the arthroscope set via the anteromedial portal and the guide for ACL reconstruction through the central transtendinous one (black arrow). (ACL, anterior cruciate ligament.)

ACL-deficient knee, LET procedures overconstrained the knee and restricted internal tibial rotation when compared with the native state. In addition, isolated LET procedures did not return normal anterior stability to the ACL-deficient knee but did significantly reduce anterior tibial translation and intra-articular graft forces

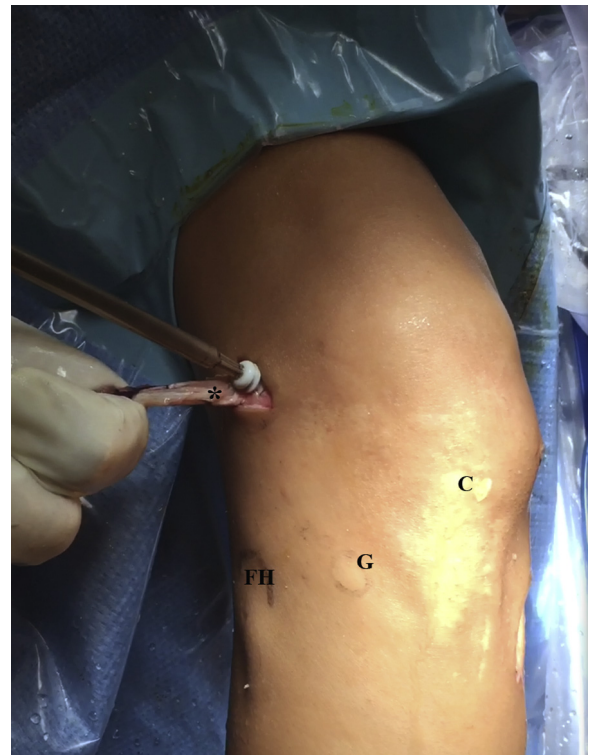


**Fig 8.** Suspension device (white arrow) (attached in its expansion piece [black arrow]) fixed to the anterior cortex of the tibia for ACL fixation (right knee). (ACL, anterior cruciate ligament; C, central transtendinous portal; M, anteromedial portal.)

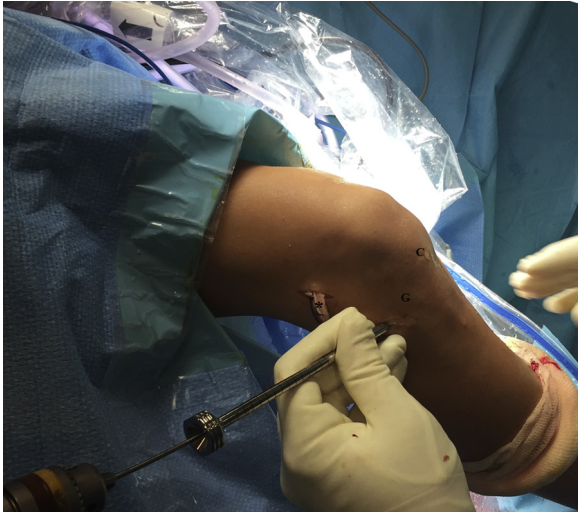
during anteriorly directed loading. Nevertheless, it must be taken into account that graft placement in this study was nonanatomic.



**Fig 7.** Placement of the guide-pin for tibial tunnel drilling, with an outside-in technique, using the approach made for hamstring tendon harvesting (right knee) (asterisk), with the arthroscope set via the central transtendinous portal (black arrow) and the guide for ACL reconstruction through the anteromedial one (red arrow). (ACL, anterior cruciate ligament.)



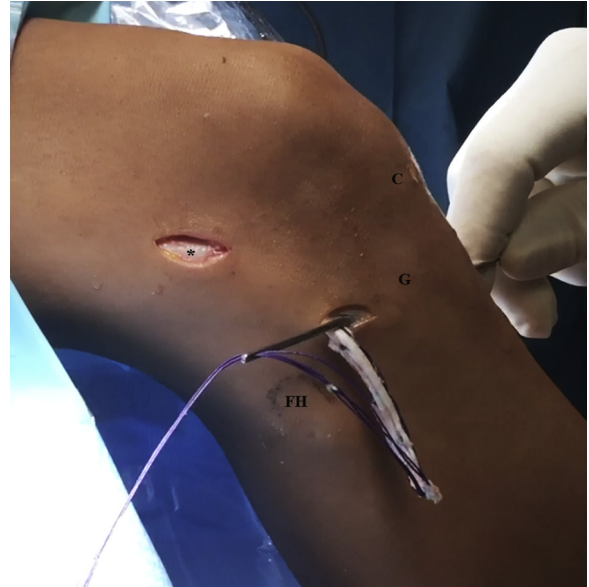**Fig 9.** Insertion of the interference screw for femoral fixation (right knee). Such a screw provides femoral fixation for both the ACL and the ALL. The remnant of the ACL graft can be seen coming out of the joint (asterisk). (ACL, anterior cruciate ligament; ALL, anterolateral ligament; C, central transtendinous portal; FH, fibular head; G, Gerdy tubercle.)



**Fig 10.** Placement of the guide-pin used for tibial tunnel drilling for the ALL reconstruction (right knee). The remnant of the ACL graft can be seen coming out of the joint (asterisk). (ACL, anterior cruciate ligament; ALL, anterolateral ligament; C, central transtendinous portal; G, Gerdy tubercle.)

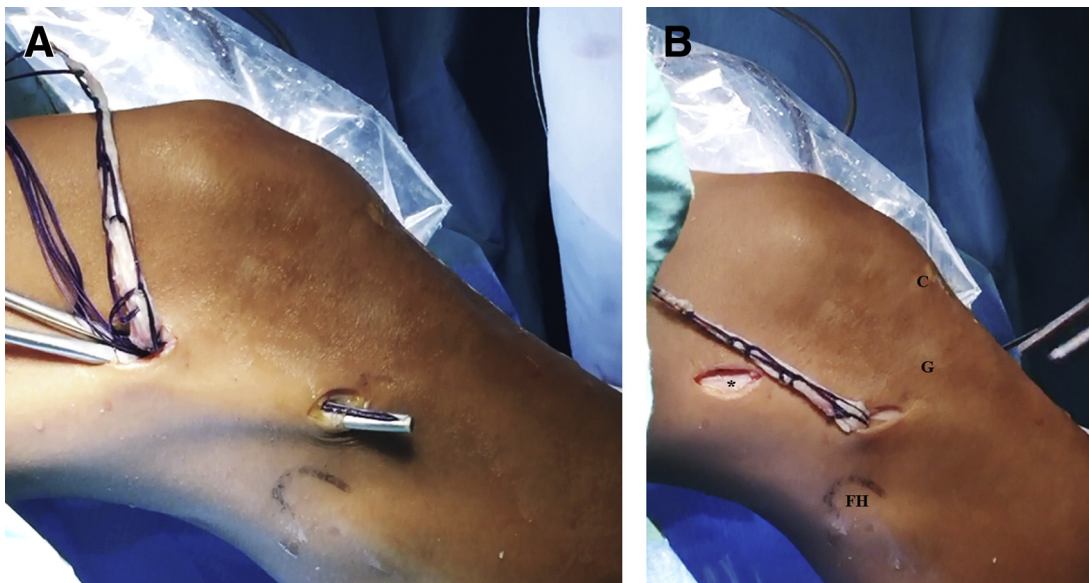
After the description of the ALL,<sup>11,17</sup> which has been referred to play an important role in the rotational stability of the knee,<sup>18</sup> several techniques have been published according to the reconstruction of such ligaments,<sup>12-15</sup> especially in association with primary ACL reconstruction in cases with clearly evident pivot shift or high-demand athletes, and in revision surgery.

However, in most of ALL reconstruction techniques, the graft employed is different from that of the ACL

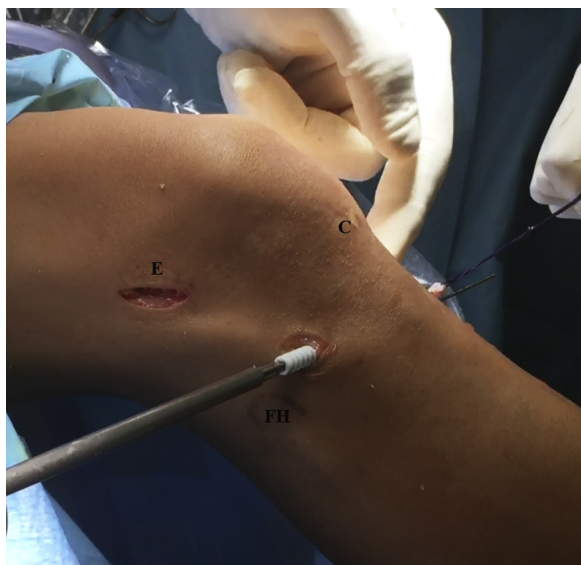

**Fig 12.** Traction threads are passed through the eyelet at the bottom of the guide-pin to be passed through the tibial tunnel made for ALL reconstruction (right knee). Asterisk: lateral approach over the epicondyle, through which the femoral tunnel is created. (ALL, anterolateral ligament; C, central transtendinous portal; FH, fibular head; G, Gerdy tubercle.)

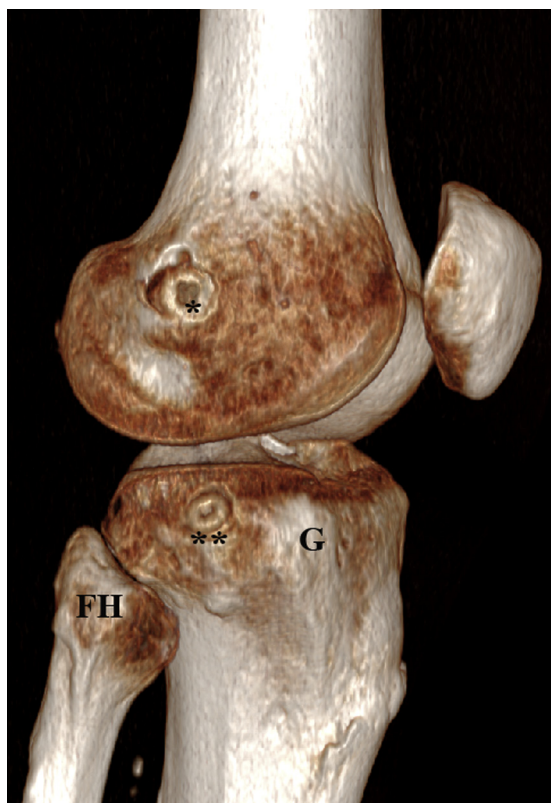
reconstruction.<sup>4,12,13</sup> This technique needs not only an additional graft but also an additional femoral tunnel and fixation device for it. Sonnery-Cottet et al. described a technique using autologous hamstring tendons for associated ACL and ALL reconstruction,<sup>14</sup> but the modifications made during graft preparation



**Fig 11.** Right knee. (A) The traction threads of the ALL graft is passed in a craniocaudal direction to the distal approach made for the tibial tunnel of the ALL, deep to the fascia lata. (B) The ALL graft can be seen through the approach made for the tibial tunnel of ALL reconstruction. Asterisk: lateral approach over the epicondyle, through which the femoral tunnel is created. (ALL, anterolateral ligament; C, central transtendinous portal; FH, fibular head; G, Gerdy tubercle.)



**Fig 13.** Fixation of the tibial end of the ALL graft with a bioabsorbable interference screw (right knee). (ALL, anterolateral ligament; C, central transtendinous portal; E, lateral approach over the epicondyle, through which the femoral tunnel is created; FH, fibular head; G, Gerdy's tubercle.)



**Fig 14.** Three-dimensional reconstruction of a CT scan performed on a knee operated using the present technique. Asterisk: femoral fixation with bioabsorbable screw; double asterisk: tibial fixation of the anterolateral ligament. (FH, fibular head; G, Gerdy's tubercle.)

**Table 2.** Advantages and Disadvantages

**Advantages**

- The main advantage of this technique is that the loop's length can be adapted to the graft's and tunnel's length, allowing associated ACL and ALL reconstruction with a single graft by increasing the length of the loop.
- Anatomic position of both ligaments can be easily achieved because they are performed independently using their original footprints.
- One single tunnel is created and a single device is used for femoral fixation, avoiding the risk of confluence.

**Disadvantages**

- The tibial fixation device must be combined with another device of additional length.
- Tunnels are created in an outside-in direction, so 3 incisions (1 femoral and 2 tibial) are needed.
- In cases with too short length or breakage of hamstring tendons, an additional graft may be needed.

ACL, anterior cruciate ligament; ALL, anterolateral ligament.

may hinder the technique and increase the surgical exposure.

In the technique here shown hamstring tendons are used in the same manner as in isolated ACL reconstruction,<sup>19</sup> only changing the length of both ends, which are prepared asymmetrically (leaving approximately one-third of the length for the short end and two-thirds for the long one); in a, for example, 27-cm-long graft, a 9-cm-long and double-diameter graft would be prepared for ACL reconstruction and a 9-cm-long and single-diameter graft would remain for ALL reconstruction. In cases with short length tendons, the loop length of the suspension device would be increased. Moreover, the inversion of the fixation (using the suspension device on the tibial site) allows a single femoral tunnel for both ligaments' reconstruction using an interference screw for fixation.

A possible drawback of this technique is the need for an expansion piece attached to the suspension device

**Table 3.** Tips, Pearls, and Pitfalls

**Tips and Pearls**

- Though not essential, the authors recommend that the central portal be used to ensure a clear view of the intercondylar notch.
- Once the graft is in place, one should check that the device is properly supported by the tibial cortex.

**Pitfalls**

- During its passage through the tunnels, the graft may become snagged. To avoid this, the graft should be passed symmetrically and, once passed, one of the ends should be pulled until the other end is at the level of the femoral cortex, to provide the longest length to the ALL arm.
- In addition, one should check that the graft can be passed with ease through the diameter calibrator. If this is not possible, the authors recommend to enlarge the tunnel's diameter by passing the drill bit through the tunnel 1 or 2 more times or by using a drill bit 0.5 mm wider than the graft.

ALL, anterolateral ligament.

because a single-diameter tunnel is employed. This could be avoided by drilling the tibial tunnel in a retrograde manner without drilling the anterior cortex of the tibia, so a common suspension device could be used, without its expansion piece. The forces placed on this technique could also be challenged. Nevertheless, the fixation devices used in this technique have been previously described and proven as a means of fixation for ligament reconstructions.<sup>20,21</sup>

## References

1. Crawford SN, Waterman BR, Lubowitz JH. Long-term failure of anterior cruciate ligament reconstruction. *Arthroscopy* 2013;29:1566-1571.
2. Bressy G, Brun V, Ferrier A, et al. Lack of stability at more than 12 months of follow-up after anterior cruciate ligament reconstruction using all-inside quadruple-stranded semitendinosus graft with adjustable cortical button fixation in both femoral and tibial sides. *Orthop Traumatol Surg Res* 2016;102:867-872.
3. Bedi A, Musahl V, Steuber V, et al. Transtibial versus anteromedial portal reaming in anterior cruciate ligament reconstruction: An anatomic and biomechanical evaluation of surgical technique. *Arthroscopy* 2011;27:380-390.
4. Lemaire M. Chronic knee instability. Technics and results of ligament plasty in sports injuries. *J Chir (Paris)* 1975;110:281-329.
5. Espejo A, Moro JA, Montáñez E, De la Varga V, Urbano V, Queipo de Llano A. Ligamentoplastia trifascicular del ligamento cruzado anterior con tendones de la pata de ganso. *Cuadernos de Artroscopia* 1995;2:35-40.
6. Hara K, Kubo T, Sugino-shita T, Shimizu C, Hirasawa Y. Reconstruction of the anterior cruciate ligament using a double bundle. *Arthroscopy* 2000;16:860-864.
7. Espejo-Baena A, Serrano-Fernandez JM, de la Torre-Solis F, Irizar-Jimenez S. Anatomic double-bundle ACL reconstruction with femoral cortical bone bridge support using hamstrings. *Knee Surg Sports Traumatol Arthrosc* 2009;17:157-161.
8. Gadikota HR, Seon JK, Kozanek M, et al. Biomechanical comparison of single-tunnel-double-bundle and single-bundle anterior cruciate ligament reconstructions. *Am J Sports Med* 2009;37:962-969.
9. Hussein M, van Eck CF, Cretnik A, Dinevski D, Fu FH. Prospective randomized clinical evaluation of conventional single-bundle, anatomic single-bundle, and anatomic double-bundle anterior cruciate ligament reconstruction: 281 cases with 3- to 5-year follow-up. *Am J Sports Med* 2012;40:512-520.
10. Li YL, Ning GZ, Wu Q, et al. Single-bundle or double-bundle for anterior cruciate ligament reconstruction: A meta-analysis. *Knee* 2014;21:28-37.
11. Claes S, Vereecke E, Maes M, Victor J, Verdonk P, Bellemans J. Anatomy of the anterolateral ligament of the knee. *J Anat* 2013;223:321-328.
12. Chahla J, Menge TJ, Mitchell JJ, Dean CS, LaPrade RF. Anterolateral ligament reconstruction technique: An anatomic-based approach. *Arthrosc Tech* 2016;5:e453-e457.
13. Wagih AM, Elguindy AM. Percutaneous reconstruction of the anterolateral ligament of the knee with a polyester tape. *Arthrosc Tech* 2016;5:e691-e697.
14. Sonnery-Cottet B, Daggett M, Helito CP, Fayard JM, Thaunat M. Combined anterior cruciate ligament and anterolateral ligament reconstruction. *Arthrosc Tech* 2016;5:e1253-e1259.
15. Sonnery-Cottet B, Barbosa NC, Tuteja S, Daggett M, Kajetanek C, Thaunat M. Minimally invasive anterolateral ligament reconstruction in the setting of anterior cruciate ligament injury. *Arthrosc Tech* 2016;5:e211-e215.
16. Slette EL, Mikula JD, Schon JM, et al. Biomechanical results of lateral extra-articular tenodesis procedures of the knee: A systematic review. *Arthroscopy* 2016;32:2592-2611.
17. Vincent JP, Magnussen RA, Gezmez F, et al. The anterolateral ligament of the human knee: An anatomic and histologic study. *Knee Surg Sports Traumatol Arthrosc* 2012;20:147-152.
18. Van der Watt L, Khan M, Rothrauff BB, et al. The structure and function of the anterolateral ligament of the knee: A systematic review. *Arthroscopy* 2015;31:569-582.
19. Espejo-Baena A, Espejo-Reina A. Anatomic outside-in anterior cruciate ligament reconstruction using a suspension device for femoral fixation. *Arthrosc Tech* 2014;3:e265-e269.
20. Prado M, Martín-Castilla B, Espejo-Reina A, Serrano-Fernández JM, Pérez-Blanca A, Ezquerro F. Close-looped graft suturing improves mechanical properties of interference screw fixation in ACL reconstruction. *Knee Surg Sports Traumatol Arthrosc* 2013;21:476-484.
21. Lee YS, Han SH, Kim JH. A biomechanical comparison of tibial back side fixation between suspensory and expansion mechanisms in trans-tibial posterior cruciate ligament reconstruction. *Knee* 2012;19:55-59.